

---

*Case Report*

## Successful Continuation of Peritoneal Dialysis after "Sweet" Hydrothorax

Utku Erdem Soyaltin, Ferhat Ekinici, Denizhan Ayatan, Cihangir Turemis, Mustafa Yildirim and Harun Akar

Tepecik Education and Research Hospital, Internal Medicine Clinic, Izmir, Turkey

---

### Abstract

A 44-year-old woman with end-stage renal disease presented with dyspnea on exertion and a vague chest pain about two weeks after commencing continuous ambulatory peritoneal dialysis (CAPD) four months ago. A chest x-ray revealed massive unilateral right-sided pleural effusion. Laboratory analysis of the effusion revealed low protein and lactate dehydrogenase but elevated glucose levels were consistent with transudate and pleuro-peritoneal leakage. Pleural glucose concentration was much higher than patients' serum glucose concentration, which was suggestive of "sweet" hydrothorax because of this high glucose concentration. It is advisable to keep this condition in mind among the differential diagnoses of hydrothorax in patients on CAPD.

**Key words:** peritoneal dialysis, sweet hydrothorax, pleural effusion

---

### Introduction

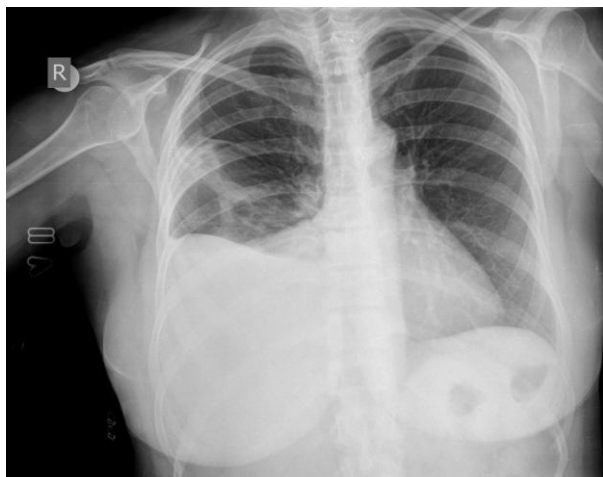
Pleural effusion is rarely caused by peritoneal dialysis (PD). Approximately 2% of all continuous ambulatory peritoneal dialysis (CAPD) patients develop massive transudative pleural effusion [1]. Hydrothorax in this situation is called "sweet hydrothorax" as hypertonic glucose solution fills the pleura [2,3]. Efforts to treat what is erroneously diagnosed as fluid overload with more hypertonic solutions lead to massive pleural accumulation of this solution together with ultrafiltrate. This phenomenon appears to be due to an increased intra-abdominal pressure in the setting of congenital or acquired diaphragmatic defects [4]. In 2003, Tang *et al.* described a series of CAPD patients with hydrothorax due to pleuroperitoneal communications. Hydrothorax developed in this group within mean 5.8 months after the start of peritoneal dialysis [5]. Hydrothorax frequently presents as respiratory distress, particularly dyspnea, or shortness of breath. The lung collapses under extreme conditions.

Approximately 25% of patients remain asymptomatic. This report describes a case of a 44-year-old female patient on peritoneal dialysis presenting with dyspnea and unilateral right-sided pleural effusion, which was eventually diagnosed as "sweet" hydrothorax.

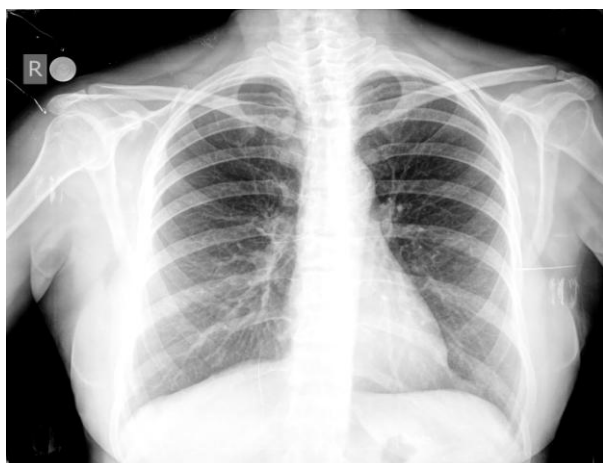### Case Report

A 44-year-old female CAPD patient was admitted to the Internal medicine clinic because of worsening dyspnea on exertion and a vague chest pain. Her past medical history revealed hypertension. She was started CAPD treatment four months ago. She was hemodynamically stable and not tachypneic, she was afebrile and her percutaneous oxygen saturation was 96% when she was breathing in ambient air. There was no jugular venous distension and there were no signs of congestive heart failure. Decreased breath sounds at auscultation and dullness on percussion were noticed at the right side. Cardiac examination was normal. A chest X-ray demonstrated a massive right-sided pleural effusion (Figure 1a and 1b). Laboratory evaluation demonstrated pronounced renal dysfunction, a white-cell count of 7.4 per cubic millimeter and a CRP value of 0.8 mg/dl (Table 1). Diagnostic thoracentesis revealed a crystal clear pleural fluid with a high glucose concentration of 271 mg/dl. The pleural-fluid protein was 0.3 g/dL and according to Light's criteria the fluid appeared to be a transudate (Table 2). Cytological and microbiological examination of the pleural fluid showed no abnormalities. The high pleural-fluid and serum-glucose ratio confirmed the clinical suspicion of a pleuroperitoneal leak. Peritoneal scintigraphy was performed and pleuroperitoneal communications were seen at the right side. Contrast-enhanced CT scanning did not show diaphragmatic hernias (Figure 2). Since the patient refused to shift to hemodialysis, we reduced peritoneal dialysis fluid volume, dwell time and increased the frequency of change. After one week chest radiography showed a complete resolution of pleural effusions and patient's symptoms.

The patient was followed-up for five months after discharge. Pleural effusion did not recur again.



**Fig. 1a.** Chest radiograph demonstrating right-sided pleural effusion in patient



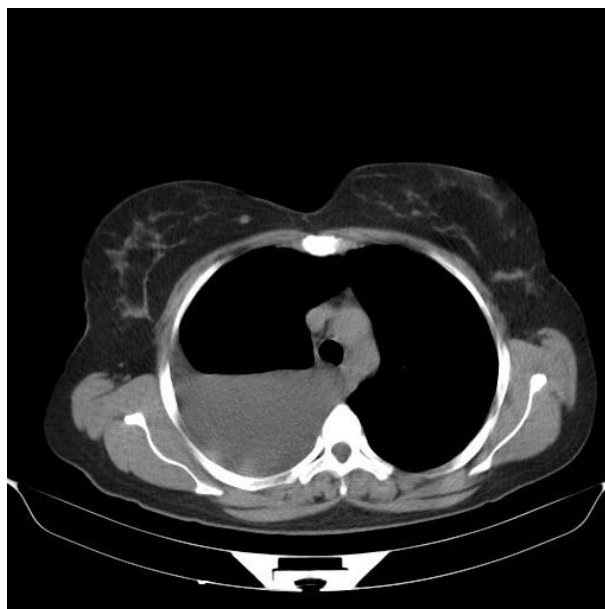
**Fig. 1b.** Chest X ray of the patient after one week

**Table 1.** Results of chemical analysis of simultaneously drawn serum and pleural fluid

	Serum	Pleural Fluid
Glucose (mg/dl)	94	271
Total protein (g/dl)	7.2	0.3
Albumin	4.2	0.1
Lactic dehydrogenase (U/L)	219	13

**Table 2.** Results of the laboratory parameters

Parameters	
Urea mg/dl	72
Creatinine mg/dl	8,4
Sodium mmol/L	132
Potassium mmol/L	3.63
Aspartate aminotransferase U/L	12
Alanine aminotransferase U/L	9
White Blood Cell 10 <sup>3</sup> u/L	15.1
Hemoglobin gr/dl	12.6
Thrombocytes 10 <sup>3</sup> u/L	390
Sedimentation mm/h	45
C-Reactive Protein mg/dL	0.8



**Fig. 2.** Contrast enhanced CT with intraperitoneal infused contrast-mixed dialysate

**Discussion**

The incidence of hydrothorax in peritoneal dialysis patients is low and it usually affects the right hemithorax and there is no clear sex predominance [4]. Hydrothorax occurs uncommonly and it may occur as an acute or late complication of PD. Although the mechanism of hydrothorax is unclear, different theories have been suggested. It is proposed that in the context of chronic liver disease ascites may be transferred by lymphatics, of which the greater supply is on the right hemithorax. Alternatively there may be a direct pleuroperitoneal communication due to diaphragmatic defects [5]. Not all diaphragmatic defects leading to pleuroperitoneal communications are congenital. Some of them are acquired, due to high intraabdominal pressure.

Peritoneal dialysis should be included in the differential diagnosis of a hydrothorax of PD patients. Hydrothorax may develop several weeks or months after starting of PD [7]. Diagnostic thoracentesis and pleural-fluid analysis are often diagnostic, revealing a crystal clear pleural fluid with a low protein and a high glucose concentration. In the patient presented here, glucose concentration in the pleural fluid was much higher than that in the serum drawn concomitantly. Sweet hydrothorax is a suitable term to describe this high glucose concentration [1,8-10]. A glucose gradient of more than 50 mg/dL is a sensitive, specific, simple and convenient first-line screening test to detect the sweet hydrothorax [1]. Moreover, pleuroperitoneal leaks typically cause transudative effusions with a low LDH and cell count [12]. In terms of imaging, peritoneal scintigraphy or contrast CT peritoneography

may be used as a diagnostic tool to detect possible peritoneopleural communications [4,13,14].

There are several treatment options such as conservative option, pleurodesis or surgery. None of these has been shown to be superior and the decision depends on the patients' clinical status and their preference as in our case. Patients should also be informed about the risks and benefits of these options [15]. Pleuroperitoneal communication is a clinical situation with little relevance outside the context of PD. Thus, conservative treatment may be the most suitable option for patients who will be transferred to hemodialysis.

Conservative treatment methods to correct pleuroperitoneal communication range from reduction of peritoneal dialysate volume to transient interruption of PD treatment. Continuation of PD happens with a 50% success rate [1]. In patients with residual renal function, manipulation of the PD prescription to decrease intra-abdominal pressure results in using small volume PD exchange [16,17]. Alternatively, patients using a cycler could use both small volume and short dwell periods with a dry day [18,19]. These options may not offer adequate clearance in anuric patients. Hemodialysis offers a temporary or permanent alternative treatment modality for renal replacement if PD is ceased [20]. The absence of PD fluid in the abdomen decreases intra-abdominal pressure. Withholding PD for 4-6 weeks allows minor imperfections in the diaphragm to heal themselves [21]. Restoration of PD on a trial basis determines whether pleural effusion will reoccur.

Talc and tetracycline pleurodesis are safe and effective treatment options for pleuroperitoneal communication [22,23]. There are other treatment options such as pleurodesis with autologous blood, which has had inconsistent results [24-26].

Videoassisted thoracoscopic surgery allows for direct visualisation of the diaphragm and malformations in this area and it is reserved as the last treatment option as it is not devoid of risks [27,28].

In general, with both conservative and surgical treatment, up to 58% of patients can continue on PD treatment [21]. However, the relapse rate is generally high, which is why the results with the different treatments are not very encouraging [4,29] and a high percentage of cases require a definitive transfer to HD [30]. This means that it is not possible to give clear directions in favour of one treatment or the other.

The present report describes a case of conservatively treated hydrothorax due to pleuroperitoneal communication. The conservative treatment via reduction of peritoneal dialysate volume and dwell time appears safe and effective.

While our patient was anuric we succeeded in conservative treatment without HD and in 3 month follow-up pleural effusion did not recur again.

*Conflict of interest statement.* None declared.

## References

1. Szeto CC, Chow KM. Pathogenesis and management of hydrothorax complicating peritoneal dialysis. *Curr Opin Pulm Med* 2004; 10: 315-319.
2. Michel C, Devy A, Lavaud S, Lebargy F. A "sweet" hydrothorax. *Press Med* 2001; 30: 1401-1403.
3. Chow KM, Szeto CC, Wong TY, Li PK. Hydrothorax complicating peritoneal dialysis: diagnostic value of glucose concentration in pleural fluid aspirate. *Perit Dial Int* 2002; 22: 525-528.
4. Nomoto Y, Suga T, Nakajima K, et al. "Acute hydrothorax in continuous ambulatory peritoneal dialysis-a collaborative study of 161 centers". *American Journal of Nephrology* 1989; 9(5): 363-367.
5. Tang S, Chui WH, Tang AW, et al. Videoassisted thoracoscopic talc pleurodesis is effective for maintenance of peritoneal dialysis in acute hydrothorax complicating peritoneal dialysis. *Nephrol Dial Transplant* 2003; 18(4): 804-808.
6. Johnston RF, Loo RV. Hepatic hydrothorax Studies to determine the source of the mud and report of thirteen cases. *Ann Intern Med* 1964; 61: 385-401.
7. Krivokuca I, Lammers J-WJ, Kluijn J. Peritoneal dialysis e An unusual cause of pleural effusion ("sweet hydrothorax"). *Respiratory Medicine CME* 2009; 2: 197-200.
8. Michel C, Devy A, Lavaud F, et al. A "sweet" hydrothorax. *Presse Med* 2001; 30(28): 1401-1403.
9. Mangana P, Arvanitis D, Vlassopoulos D. Letters and replies acute hydrothorax in peritoneal dialysis patients: diagnosis and treatment options. *Nephrol Dial Transplant* 2003; 18(11): 2451-2452.
10. Tsunozuka Y, Hatakeyama S, Iwase T, Watanabe G. Video-assisted thoracoscopic treatment for pleuroperitoneal communication in peritoneal dialysis. *Eur J Cardiothorac Surg* 2001; 20(1): 205-207.
11. Light RW, Macgregor MI, Luchsinger PC, and Ball WC. Pleural effusions: the diagnostic separation of transudates and exudates. *Annals of Internal Medicine* 1972; 77(4): 507-513.
12. Garcia Ramon R and Miguel Carrasco A. "Hydrothorax in peritoneal dialysis". *Peritoneal Dialysis International* 1998; 18(1): 5-10.
13. Light RW, Broaddus VC. Pleural effusion. In: Murray JF, Nadel JA, Mason RJ, Boushey HA, eds. *Textbook of Respiratory Medicine*. 3rd ed. Philadelphia: W.B. Saunders; 2000: 2016.
14. Ramon RG, Carrasco AM. Hydrothorax in peritoneal dialysis. *Perit Dial Int* 1998; 18: 5-10.
15. Remon Rodriguez C, et al. Complicaciones propias de la tecnica: hernias, escapes, hidrotorax, hemotorax, neumotorax y quiloperitoneo. *Guías de practica clinica en dialisis peritoneal. Guías Sociedad Espanola de Nefrologia. Nefrologia* 2006; 26 (4): 1184.
16. Girault-Lataste A, Abaza M, Valentin JF. Small volume APD as alternative treatment for peritoneal leaks. *Perit Dial Int* 2004; 24:294-296.
17. Christidou F, Vayonas G. Recurrent acute hydrothorax in a CAPD patient: successful management with small volumes of dialysate [Letter]. *Perit Dial Int* 1995; 15: 389.
18. Strauss FG, Holmes DL, Dennis RL, Nortman DF. Short-dwell peritoneal dialysis: increased use and impact on clinical outcome. *Adv Perit Dial* 1993; 9: 49-51.
19. Townsend R, Fragola JA. Hydrothorax in a patient receiving continuous ambulatory peritoneal dialysis: successful treatment with intermittent peritoneal dialysis. *Arch Intern Med* 1982; 142: 1571-1572.
20. Chow KM, Szeto CC, Li PK. Management options for hydrothorax complicating peritoneal dialysis. *Semin Dial* 2003; 16: 389-394.

21. Ing A, Rutland J, Kalowski S. Spontaneous resolution of hydrothorax in continuous ambulatory peritoneal dialysis. *Nephron* 1992; 61: 247-248.
22. Okada H, Ryuzaki M, Kotaki S, *et al.* Thoracoscopic surgery and pleurodesis for pleuroperitoneal communication in patients on continuous ambulatory peritoneal dialysis. *Am J Kidney Dis* 1999; 34: 1702.
23. Benz RL, Schleifer CR. Hydrothorax in continuous ambulatory peritoneal dialysis: successful treatment with intrapleural tetracycline and a review of the literature. *Am J Kidney Dis* 1985; 5: 13640.
24. Catizone L, Zuchelli A, Zucchelli P. Hydrothorax in a PD patient: successful treatment with intrapleural autologous blood instillation. *Adv Perit Dial* 1991; 7: 8690.
25. Chao SH, Tsai TJ. Recurrent hydrothorax following repeated pleurodesis using autologous blood. *Perit Dial Int* 1993; 13: 3212.
26. Ariza M, Lopez M, Quesada T. Complications of CAPD in children: six years experience in Caracas, Venezuela. *Adv Perit Dial* 1991; 7: 26971.
27. Hosoda H, Nishio Y, Fujisaki H, Sunamori M. Videoscopic surgical treatment for the patient of pleuroperitoneal communication complicating (CAPD) [Japanese]. *Kyobu Geka* 2000; 53: 2513.
28. Allen SM, Matthews HR. Surgical treatment of massive hydrothorax complicating continuous ambulatory peritoneal dialysis. *Clin Nephrol* 1991; 36: 299301.
29. Oviedo Gomez V, Sanchez Garcia I, Martin Escuer P, *et al.* Hydrothorax in peritoneal dialysis: a rare peritonitis complication. *Nefrologia* 2010; 30(5): 5945.
30. Garcia Ramon R, Miguel Carrasco A. Hydrothorax in peritoneal dialysis. *Perit Dial Int* 1998; 18: 5405.