

---

Short communication

## Bisphosphonate - Associated Osteonecrosis (BON) in a Haemodialysis Patient With Prostate Cancer and Metastatic Bone Disease

Christidou F<sup>1</sup>, Aggelou A<sup>1</sup>, Margaritis G<sup>2</sup>, Tziata M<sup>3</sup>, Deligianidis N<sup>2</sup>, Toutsiaris C<sup>2</sup> and Bischiniotis T<sup>4</sup>

Renal <sup>1</sup>Unit, <sup>2</sup>Urology and <sup>3</sup>Radiology Department of Chalkidiki's General Hospital, "Theagenio" <sup>4</sup>Cancer Hospital of Thessaloniki, Polygyros, Greece.

---

### Abstract

**Background.** We present our experience from the management of a patient with chronic renal failure, prostate cancer with metastatic bone disease and bisphosphonate-associated osteonecrosis of the jaw (BON).

**Methods.** Our case concerns a male diabetic patient 72 years old with prostatic cancer, who was monthly treated with zoledronic acid for four years and was referred to our department because of deterioration of a preexisting renal failure. The cause of renal failure was unknown and the patient appeared with oligoanuria, peripheral edema, leucocytosis, jaundice and severe renal insufficiency. Computer tomography of the abdomen did not reveal metastatic liver disease or obstructive nephropathy. The patient started hemodialysis and five days later he complained of severe pain and swollen of the low mandible, dysphagia and persistent cough with heavy expectoration. Intraoral examination revealed an extensive area of osteonecrosis of the jaw, a panoramic radiograph confirmed pathological fracture and the CAT scan of the neck showed multiple abscesses down to the upper mediastinum.

**Results.** Following repeated punctures of the lesions, cultures were taken and multiple antibiotic treatment was administered. One month later patient's status improved and he was capable to eat smooth foods, with normal liver tests but still on haemodialysis.

**Conclusions.** There is strong evidence that bisphosphonate therapy is the common link in patients with BON. The possible pathobiological mechanisms involve the inhibition of bone remodeling and decreased intraosseous blood flow caused by bisphosphonates. The risk of developing complications appears to increase with time of use of the medication. Patients usually are asymptomatic but may experience severe pain because of the necrotic bone becoming infected secondarily, after it is exposed to the oral environment. There are no evidence based guidelines, and the clinical management of the oral complication is personalized.

**Keywords:** bisphosphonate therapy; haemodialysis; osteonecrosis of the jaw; prostate cancer

### Introduction

About 2 million people worldwide are treated with bisphosphonates (BPN) as part of a cancer therapy. Another

huge number of patients is treated with bisphosphonates in oral application for osteoporosis. BPN are given to patients with cancer to help control bone loss resulting from metastatic skeletal lesions [1,2]. They reduce skeletal-related events associated with multiple myeloma (such as fractures) and metastatic solid tumors (such as breast, lung and prostate cancers) in the bones [3]. As a result, bone turnover becomes profoundly suppressed and, over time, the bone shows little physiologic remodeling. The bone becomes brittle and unable to repair physiologic microfractures that occur in the human skeleton with daily activities. In the oral cavity, the maxilla and mandible are subjected to constant stress from masticatory forces. Thus, it is expected that physiologic microfractures occur daily in oral cavity. In a patient taking BPN, the resulting microdamage is not repaired, setting the stage for the oral osteonecrosis to occur [4].

### Case report

Our case concerns a male diabetic patient 72 years old with prostatic cancer, who was monthly treated with zoledronic acid for four years and was referred to our department because of deterioration of a preexisting renal failure.

The renal failure was of unknown origin and the patient appeared with oligoanuria, peripheral edema, leucocytosis, jaundice and severe renal insufficiency. Computer tomography of the abdomen did not reveal metastatic liver disease or obstructive nephropathy. The patient started hemodialysis and five days later he complained of severe pain and swollen of the low mandible, dysphagia and persistent cough with heavy expectoration. Intraoral examination revealed an extensive area of osteonecrosis of the mandible; a panoramic radiograph confirmed a pathological fracture and the CAT scan of the neck showed multiple abscesses down to the upper mediastinum (Figure 1, 2).

Following repeated punctures of the lesions, the cultures were positive for Klebsiella, fungus and microorganism of the oral flora and proper antibiotic treatment was administered. Liquid food supplementations were administered per os for almost a month, until he was again capable to eat smooth foods. One month later the patient improved, but remained on hemodialysis. (Figure 3, 4).

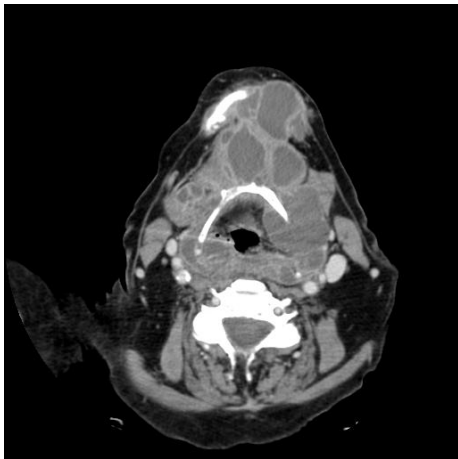


Fig. 1

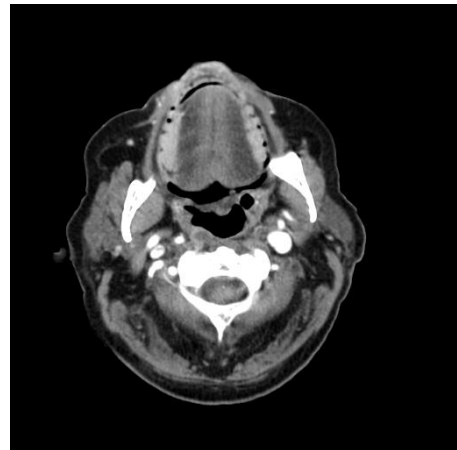


Fig. 3

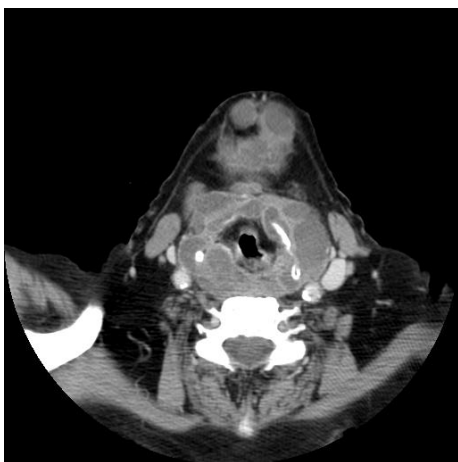


Fig. 2

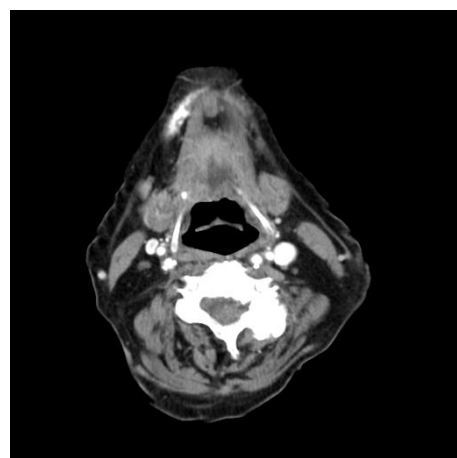


Fig. 4

## Discussion

Bisphosphonate-related osteonecrosis of the jaws (BON), is gaining importance due to the increasing indication spectrum of bisphosphonate therapy. In 2003 Tarassoff *et al.* reported that osteonecrosis of the jaws was approximately 4 times higher in a cancer population of whom many received bisphosphonate therapy [5]. In patients who develop BON spontaneously, the most common initial complaint is the sudden presence of intra-oral discomfort and the presence of roughness that may progress to traumatize the oral soft tissues surrounding the area of necrotic bone. Therefore, the diagnosis of BON is based on the medical and dental history of each patient, as well as the observation of clinical signs and symptoms of the pathological process.

Until today it remains unclear whether osteonecrosis or infection of BPN - treated bone occurs first. Most authors described a BPN-induced necrotic bone with superinfection [6]. They discussed avascular necrosis of the bone and focused on antiangiogenic effects of BPN as causing agents [7]. C. Dannemann *et al* found inflammatory signs and direct pathways for pathogens from the oral cavity into the bone in all of their patients by tooth extraction, new prosthesis or endodontic treatment. Sometimes a long time passed between dental treatment and appearance of necrotic bone, but the location was identical in all patients. The microbial investigation revealed pathogens of the physiological flora of the oral cavity as actinomyces, lactobacillus,

*candida glabrata* and others causing aggressive infection in the bone and surrounding soft tissue. Our findings were similar. These findings suggest that not bisphosphonates alone cause BON. With other synergistic factors such as microbial oral flora, they play a key-role in the pathogenesis of this new type BON in those delicate patients. Due to previous chemotherapy patients are immunocompromised, therefore more susceptible to infections [8].

In our patient the long duration of therapy with BPN, in association with renal function impairment, facilitated BON. Our treatment strategy included intensive antibiotic therapy in combination with liquid oral food intake and good fluid control with dialysis. By this way, restoration and healing of the infected areas in the oral cavity and the neck became evidence and the patient was cured. Today, six months later, our patient remains on hemodialysis due to end stage renal failure, and he is remaining asymptomatic.

Although several case reports of this drug-associated complication have been published, there have been no documented uniform treatment strategies that would yield consistent resolution and healing of BON [9]. In fact many cases had poor outcomes in spite of therapy, progressing to extensive dehiscence and exposure of bone. Treatment strategies included local surgical debridement, bone curettage, local irrigation with antibiotics and hyperbaric oxygen therapy. However, none of these therapeutic modalities has proven successful. Surgery is recommended only in symp-

tomatic patients, whereas asymptomatic patients with limited areas of uncovered bone should be treated conservatively with irrigations and antibiotic therapy and a closely monitor of their oral hygiene status. This is a treatment strategy confirmed by the majority of the rewires in this field [10].

### Conclusions

Therefore, the inability to manage lesions of BON compromises the oncological, nutritional and oral management of affected patients. Prevention of this condition is of paramount importance for these patients so that they receive the anticancer therapies so necessary for the best possible outcome of their neoplastic disease. Prevention measures are: 1) no invasive dental treatment during BPN therapy and 2) a screening examination and dental rehabilitation before starting the treatment with BPN, preventing invasive dental treatment during the period of therapy [11].

*Conflict of interest statement.* None declared.

### References

1. Migliorati CA, Casiglia J, Epstein J, *et al.* Managing the case of patients with bisphosphonate-associated osteonecrosis. *J Am Dent Assoc* 2005; 136 (12): 1658-1668.
2. Hellstein JW, Marek CL. Bisphosphonate osteonecrosis (bisphossy jaw): is this phossy jaw of the 21<sup>st</sup> century? *J Oral Maxillofac Surg* 2005; 63: 682-689.
3. Migliorati CA, Schubert MM, Peterson DE, *et al.* Bisphosphonate-associated osteonecrosis of mandibular and maxillary bone: an emerging oral complication of supportive cancer therapy. *Cancer* 2005; 104: 83-93.
4. Merigo E, Manfredi M, Meleti M, *et al.* Bone necrosis of the jaws associated with bisphosphonate treatment: a report of twenty-nine cases. *Acta Biomed* 2006; 77: 109-117.
5. Dannemann C, Grätz KW, Riener MO, Zwahlen RA. Jaw osteonecrosis related to bisphosphonate therapy: a severe secondary disorder. *Bone* 2007; 40(4): 828-34.
6. Bagan JV, Murillo J, Jimenez Y, Poveda R, Milian MA, Sanchis JM, *et al.* Avascular jaw osteonecrosis in association with cancer chemotherapy: series of 10 cases. Review. *J Oral Pathol Med* 2005; 34: 120-3.
7. Assael LA. New foundations in understanding osteonecrosis of the jaws. *J Oral Maxillofac Surgery* 2004; 62: 125.
8. C. Dannemann, K. W. Grötz, R. Zwahlen. Clinical experiences with bisphosphonate-induced osteochemonecrosis of the jaws. A new entity for clinicians. *Swiss Med Wkly* 2006; 136: 504-509.
9. Schuster MW, Dymek JM. Oral cavity avascular bone necrosis: a newly recognized complication of intravenous bisphosphonate therapy in cancer patients (Abstract 4905). *Blood* 2004; 104 (11).
10. Ruggiero SL, Mehrotra B, Rosenberg TJ, Engroff SL. Osteonecrosis of the jaws associated with the use of bisphosphonates: a review of 63 cases. *J Oral Maxillofac Surg* 2004; 62: 527-34.
11. Migliorati C SM, Douglas E, Seneda L. Bisphosphonate-associated osteonecrosis of mandibular and maxillary bone. An emerging oral complication of supportive cancer therapy. *Am Cancer Soc* 2005; 104: 83-93.